



PATIENT

Bear Bailey

SPECIES

Canine

BREED

Chihuahua

PRESENTING CLINICAL SIGNS

- Anorectic, gradually getting worse.
- Exam: icteric, slightly lethargic. Rest of exam unremarkable.
- CBC: PCV 43.5% WBC 8000
- Chem: Significant liver pathology: decreased BUN, Creat. Elevated liver enzymes (ALT 2162, AST 187 ALP 2459). Bilirubin total 7.8 conjugated 5 unconjugated 2.8. Albumin 2.5 Cholesterol 1258
- UA: SG 1.017 protein 1+ bili 3+ T4 1.4
- Current Medications None
- Radiographic Findings None

ULTRASONOGRAPHIC EXAMINATION OF THE ABDOMEN

SEX

MN

AGE

11yr

WEIGHT

10.58lb

INTERPRETED BY

R. McKenzie Daniel,
DVM, DABVP
(Canine and Feline)

IMAGING PERFORMED BY

Sara Hansen

HOSPITAL NAME

Cottage Grove VC

REFERRING VET

Dr Damewood

INVOICE
24026

DATE
02/27/2026

Urinary System

The urinary bladder, trigone, cystourethral junction, and visible pelvic urethra exhibited normal thickness and tone. Anechoic urine was present in the lumen with no evidence of urine/lumen sediment, mineral, or calculi. The ureteral papillae were normal. The ureters were not visible which is normal. No evidence of inflammatory or neoplastic changes was noted.

The residual prostate appeared normal and free of pathology.

Normal size and margination were present in the kidneys. A normal 1:3 cortex / medulla ratio was maintained. The medulla and cortices were uniform in texture with some increased echogenicity and mild loss of corticomedullary symmetry and definition expected for the age of the patient. No evidence of pelvic dilation was present. Bilateral areas of pinpoint medullary mineral were present. The left kidney measured 4.1 cm in length. The right kidney measured 4.0 cm in length.

The area of the aortic trifurcation was free of pathology.

Adrenal Glands

The bilateral adrenal glands were mildly enlarged in size. Mild parenchyma heterogeneity and mild capsule asymmetry was present without suspicion for overt neoplasia. The left adrenal gland measured 0.77 cm width in the caudal pole. The right adrenal gland subjectively measured 0.77 cm width in the caudal pole.

Spleen

The spleen exhibited a finely textured and homogenous parenchyma which was hyperechoic to the liver and renal cortical parenchyma. The capsule was smooth and regular without apparent expansion. The splenic vasculature at the hilus was normal in volume with no evidence of congestion or thrombosis. Acute to chronic inflammatory, neoplastic, or benign parenchyma changes were not noted.

Liver/Gallbladder

The liver was subjectively normal in size with areas of asymmetrical ventral and caudal hepatic capsule contour. Non-homogenous parenchyma exhibiting variable coarse echotexture was present. The gallbladder was mildly distended in size with normal walls and mild non-dependent to focally



PATIENT

Bear Bailey

congealed possibly adhered caudal lumen gallbladder debris. No evidence of gallbladder wall edema was present. The common bile duct was not visualized without overt evidence of dilation or post hepatic obstructive criteria.

SPECIES

Canine

Gastrointestinal

The stomach presented borderline thickened wall. Intact wall layering was maintained and distinct. The stomach contained mild to moderate retained anechoic to echogenic fluid and mild hyperechoic ingesta.

BREED

Chihuahua

The small intestine presented intact wall layering with 1:3 muscularis/mucosa ratio. The lumen of the small intestine was empty with no signs of mechanical/metabolic ileus, obstruction or foreign material.

Normal visible colon wall layers were present with apparent formed feces in lumen.

SEX

MN

Pancreas

The left pancreas was sonographically normal.

AGE

11yr

Free Abdomen

Unspecified non-homogenous small mass area in the of caudal liver and pancreas was present measuring 3 cm in diameter.

Generalized mild omental hyperechogenicity.

WEIGHT

10.58lb

Intermittent scant pockets of peritoneal effusion.

ULTRASONOGRAPHIC FINDINGS

INTERPRETED BY

R. McKenzie Daniel,
DVM, DABVP
(Canine and Feline)

Primary

- Non-homogenous hepatopathy
- Non-edematous gallbladder with mild non-organized bile debris- not consistent with mature mucocele
- Unspecified non-homogenous mass area of caudal liver / pancreas
- Hypomotile stomach with retained fluid / ingesta, normal empty small intestine
- Mild bilateral adrenomegaly
- Mild inflamed omentum and scant peritoneal effusion

IMAGING PERFORMED BY

Sara Hansen

Secondary

- Bilateral chronic renal changes

HOSPITAL NAME

Cottage Grove VC

INTERPRETATION OF THE FINDINGS & FURTHER RECOMMENDATIONS

REFERRING VET

Dr Damewood

Chronic to acute on chronic hepatic inflammation, vacuolar changes, cholestasis, hyperplasia, neoplasia, all potentials. Hepatic or pancreatic origin with possible enlarged non-homogenous lymph node favored for the unspecified perihepatic to peripancreatic mass.

INVOICE
24026

Assuming normal clotting status and using 25ga needle, hepatic and if accessible mass FNA cytology is

DATE

02/27/2026



PATIENT

Bear Bailey

warranted for further clarification. Secondary metabolic or functional gastric ileus favored without overt visualized pyloric or post-hepatic obstruction. A spec cPL is recommended.

SPECIES

Canine

Hepatogastrintestinal support with clinical and sonographic monitoring of the liver and gastrointestinal tract would be reasonable with recheck indicated if evidence of progressive hepatopathy or icterus. A guarded prognosis is suspected pending suggested sampling.

BREED

Chihuahua

SEX

MN

AGE

11yr

WEIGHT

10.58lb

INTERPRETED BY

R. McKenzie Daniel,
 DVM, DABVP
 (Canine and Feline)

IMAGING PERFORMED BY

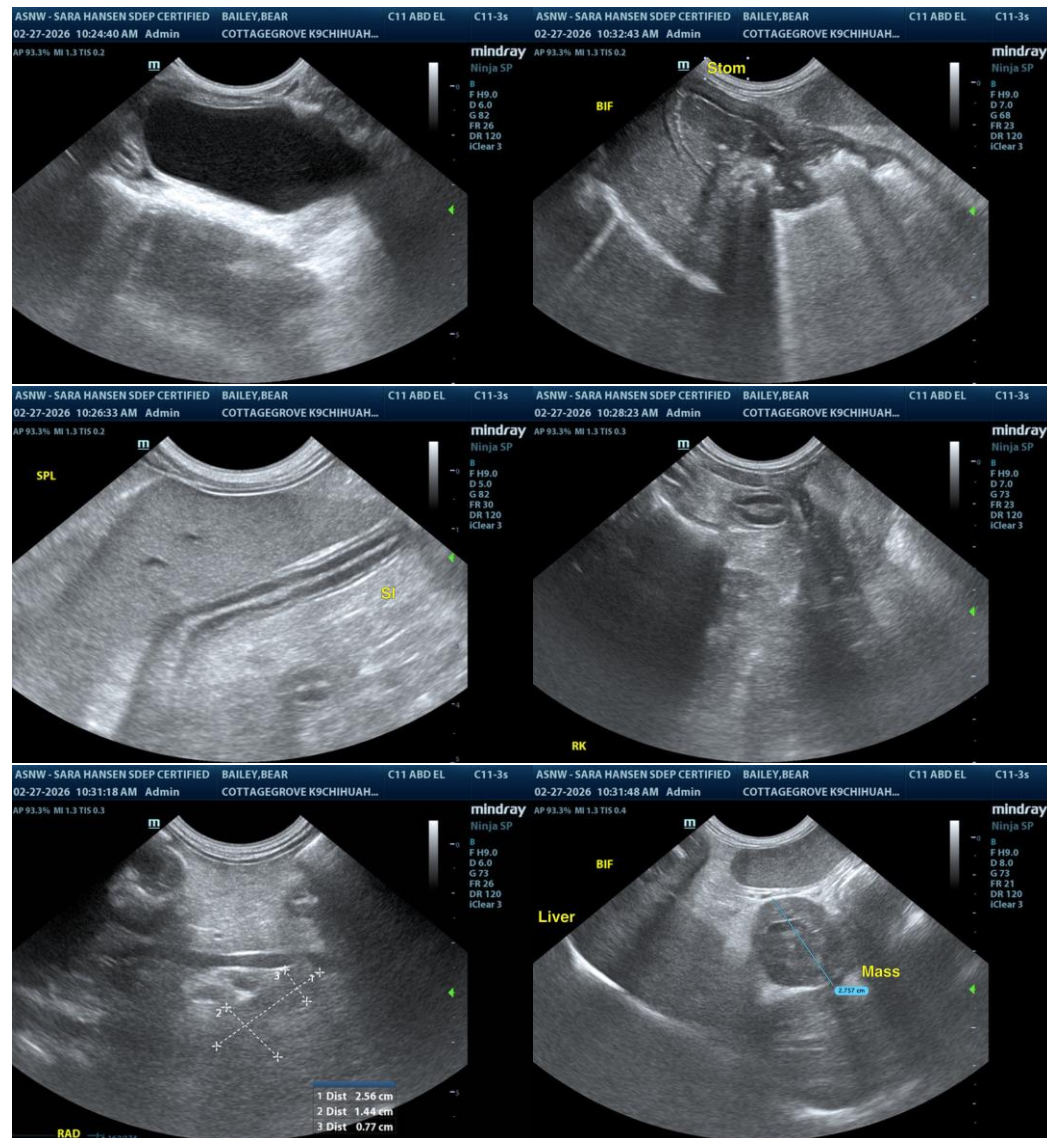
Sara Hansen

HOSPITAL NAME

Cottage Grove VC

REFERRING VET

Dr Damewood



INVOICE
 24026

DATE
 02/27/2026



PATIENT

Bear Bailey

SPECIES

Canine

BREED

Chihuahua

SEX

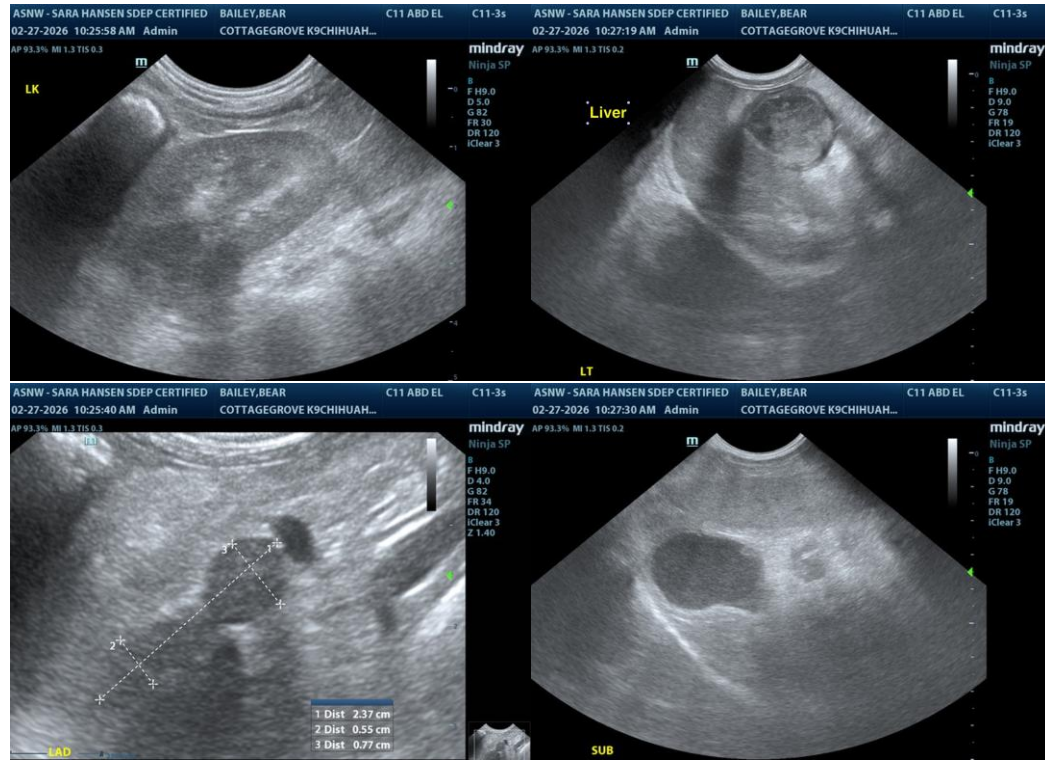
MN

AGE

11yr

WEIGHT

10.58lb



INTERPRETED BY

R. McKenzie Daniel,
 DVM, DABVP
 (Canine and Feline)

IMAGING PERFORMED BY

Sara Hansen

HOSPITAL NAME

Cottage Grove VC

REFERRING VET

Dr Damewood

INVOICE
 24026

DATE
 02/27/2026

The information and recommendations provided are based on the images presented by the referring veterinarian/sonographer. No evaluation can be communicated regarding pathology that was not visible in the image/video clips provided.

Thank you for this referral. If the clinical or image interpretation does not parallel your findings or if I can be of any further assistance, please contact me.

R. McKenzie Daniel, DVM, DABVP (Canine/Feline Practice)
info@sonopath.com